

Pterodactyling: A novel surgical approach to alleviating body dysmorphia in young men concerned with their perceived lack of elbow length

Umico Niwa

Abstract—The purpose of this study is to discuss Medial Epicondyle Elongation Surgery (MEES), the keystone of the treatment of patients with Body Dysmorphic Disorder (BDD) who are specifically concerned with their perceived lack of elbow length. These individuals colloquially known as "Pterosaurs" have been on the rise in recent years. The use of our prediagnostic tool, the Body Image Satisfaction Index (BISI), allows for early recognition of stray nodal points in patients diagnosed with BDD. As a result, many patients can receive successful early treatment so as to avoid the need for a more radical surgical correction at a later stage. Cosmetic surgeons should familiarize themselves with the BISI test in order to empirically assess the severity of Body Dysmorphia (BD) experienced by each patient so as to tailor an Epicondyle Elongation Prosthetic (EEP) of custom length inversely correlating to the Dysmorphic Degree Values (DDV) on the nodal point associated with the elbow to achieve maximal patient satisfaction.

Index Terms—Pterodactyling, Medial Epicondyle Elongation Surgery, Body Dysmorphic Disorder, Nodal Cascation

I. INTRODUCTION

Body dysmorphic disorder (BDD), a psychological disorder in which a person becomes obsessed with imaginary defects in their appearance, has been described for over a century and reported in various medical literature, yet it continues to remain underdiagnosed. [1] [2] In the past fifteen years, there has been a spike in young men afflicted with body dysmorphia, localized to the elbow region, these subjects refer to themselves as "Pterosaurs". Figure 1 While clinicians have unanimously noted that this specific, highly localized dysmorphia is emergent and real, the exact cause of this shift in body image expectation for those afflicted remains unclear.

Despite the root cause being unclear, treatment is frequently sought out by those afflicted, particularly by patients whose elbows are less protruded at birth. Medial Epicondyle Elongation Surgery (MEES), popularly known as "Pterodactyling", has become a routine treatment for men suffering from chronic low self-esteem stemming from their dysmorphia.. The MEES procedure is now widely accepted as routine and therapeutic, but individuals considering MEES and the caregivers who serve as their advisors and medical gatekeepers still have little reliable information concerning the long term outcomes to these surgeries. [3] Though groups such as the Pterosaur Recovery Association (PRA) promulgate their own privately researched Standards of Care for the provision of MEES, caregivers lack empirical information to assess the validity

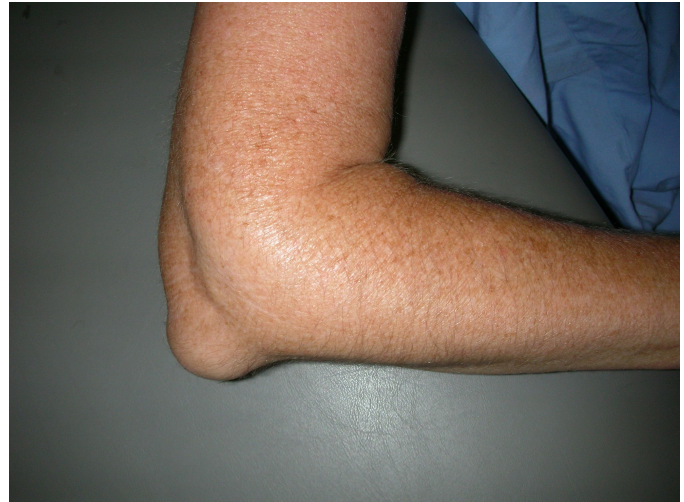

Fig. 1. Six weeks post-operative appearance of a patient who had undergone minimal medial epicondyle elongation surgery.

of their recommendations causing confusion and hesitation around the operation.

The primary method of initial diagnosis for undiagnosed pterosaurs is the Body Image Satisfaction Index (BISI) test. Because it is readily available online, it serves as a strong and empowering prediagnostic tool for preliminary self-assessment. [4] Though BISI tests initially emerged from the field of transgender medical studies, they are now commonly used as an empirical diagnostic tool in various medical fields. Lindgren and Pauly (1975) were the first to quantify the feelings of transgender individuals about their bodies for medical use. [5] They developed the original Body Image Scale for Transsexuals, which was then modified and broadened for use in the general population to measure body satisfaction. BISI theory re-categorizes and projects the human body as a series of mutable nodal points Figure 2

Using the BISI method, surgeons are able to assess and prescribe customized surgical options and prosthesis to bypass the "one-size-fits-all" approach [6] that was typically seen utilized in body dysmorphia (BD) corrective surgeries of the past.

II. METHODS & MATERIALS

The study examined by this article was performed between 2007 and 2018 by Carleson and Jaime. A total pool of 305

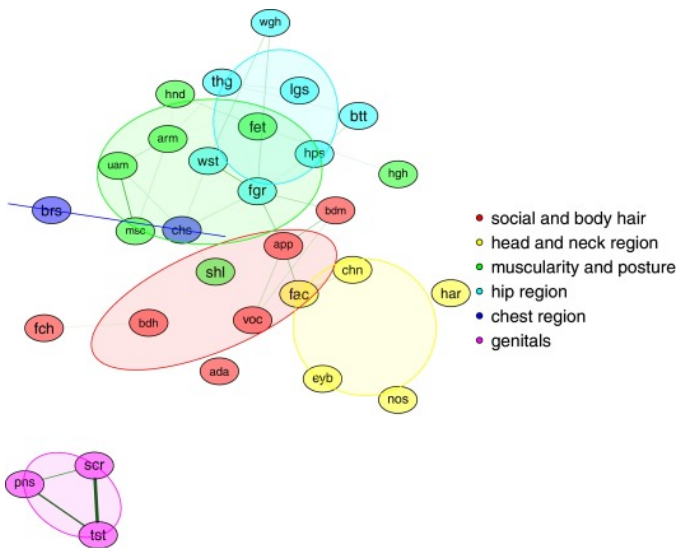


Fig. 2. Network representation of male-to-female body satisfaction. *Legend:* $n = 308$; green edges represent positive inter-item correlations of $r > .40$, line width corresponds with the strength of the correlation. Node position represents item centrality. Node colour and overarching ovals mark subscales. ada = Adam’s apple, app = appearance, arm = arms, bdh = body hair, bdm = body movement, brs = breast, btt = bottom, chn = chin, chs = chest size, eyb = eye brows, fac = face, fch = facial hair, fet = feet, fgr = figure, har = hair, hgh = height, hnd = hands, hps = hips, lgs = legs, msc = muscles, nos = nose, pns = penis, scr = scrotum, shl = shoulders, thg = thighs, tst = testicles, uam = upper arm muscles, voc = voice, wgh = weight, and wst = waist.

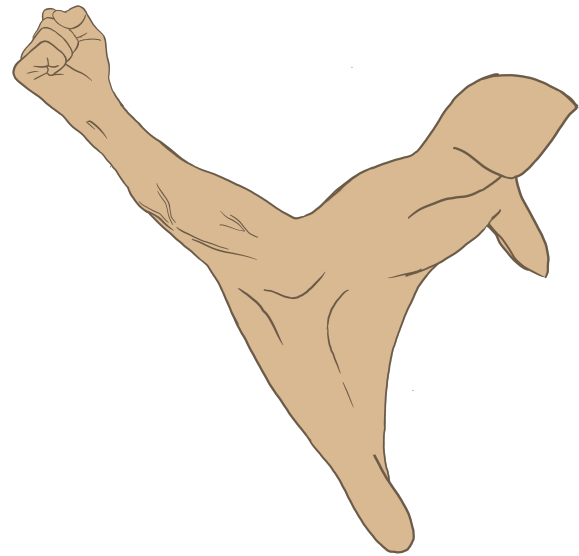


Fig. 4. Illustration of postoperative pterosaur arm.

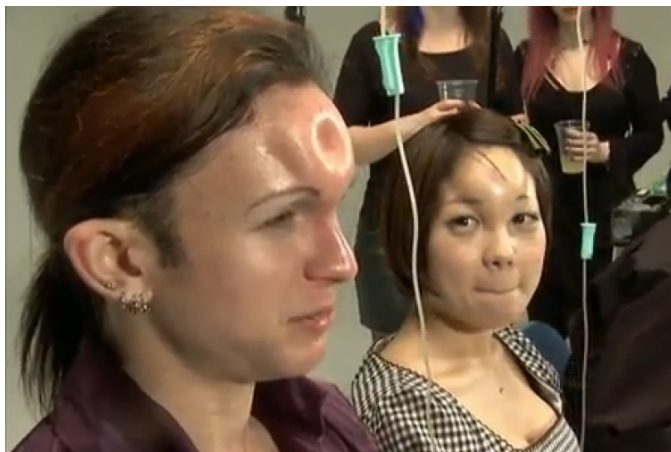

Fig. 3. Photograph of successful bagel-heading.

men diagnosed with body dysmorphic disorder (BDD) based low self-esteem who desire for the pterodactyling surgery were given BISI tests in early 2007. 72 of the polled men went on to, over the next 3 years, receive the pterodactyling surgery. The group of 72 pterosaurs were then polled against 223 pre-operative men over the course of 9 years. [7] A specialized BISI test utilizing the nodal point based body satisfactory tests was taken every six months by both groups. Figure 5

It measured body satisfaction of each participant every six months and compared the updated scores against their own pre-surgical score, their peers’ scores, and the scores of the men who never received the surgery. [8]

The surgery itself is a delicate and lengthy form of modified arthroscopy. Because of the relatively large size of the

metal pterodactyl implant, open surgery is required, rendering modern methods of arthroscopy impossible. [9] The specific length and shape of the implant is honed by the results of repeated BISI nodal testing in the months prior.

A long incision is made along the outside of the elbow revealing the anconeus muscle and olecranon of the ulna. [10] The surrounding muscular structures and the anterior olecranon crest is drilled hollow. The porous-coated ulnar implant is inserted and bolted into place along the length of the ulna. The olecranon fossa of the humerus is shaved down to accommodate the new prosthetic. Figure 6

The muscles of the area are carefully placed over the prosthetic insert and, depending on the size of the new pterodactyl wing, either a stepped gauging system is used to extend the length of the new appendage or, in extreme cases, skin grafts from the inner thigh of the patient are used in the suturing process and a mesh of ligaments is placed underneath. [11]




Fig. 5. Simplified nodal network diagram of person exhibiting need for pterodactyling.

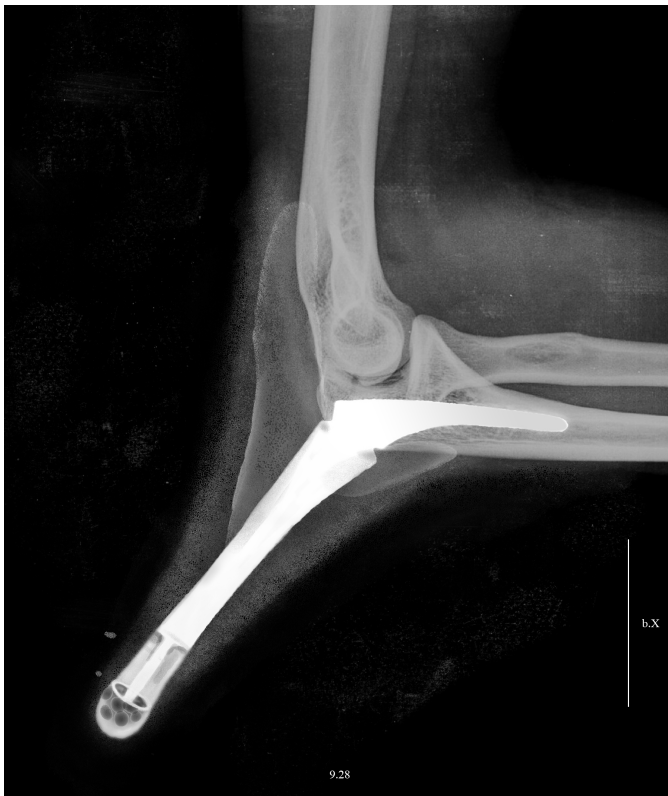

Fig. 6. X-ray of a successful medial epicondyle elongation surgery using an implant made of the material, BioloX[®] Delta, an alumina matrix composite consisting of approximately 75% alumina and roughly 25% yttria-stabilized tetragonal polycrystalline zirconia (Y-TZP). There is very little swelling due to the use of human tissue-engineered vascular grafts (TEVGs) at the sites of incision.

The surgeon should specialize in MEES in order to achieve results with minimal scarring, improving the image of the patient.

III. RESULTS & DISCUSSION

Of the 72 pterosaurs in the study, all 72 went on to report a higher level of satisfaction with not only their bodies, but their lives afterwards. In fact, the postoperative BISI tests taken show increased body satisfaction across the board.

The men unable to receive the surgery, as the number of visible pterosaur men increase in society, report sensations of a “phantom [pterodactyl] wing” jutting from their elbow. [12]

The examined study by Carleson and Jaime, while pushing forward the legitimacy and recognition of pterosaurs, was disappointingly narrow in its scope. The study was limited to a one-dimensional measurement of body image, namely body satisfaction in exclusivity.

There is currently a need for future studies that take into account a variety of body satisfaction behaviors, including desire for further modification beyond pterodactyling, lifestyle factors, medical complications, length of time of social reintegration, and long term mental health follow ups among other criteria to test the validity and reliability of body dissatisfaction and body image satisfaction measures. Future studies also should take into account participants’ beliefs about the effectiveness and the potential risks of certain interventions.

The benefits of surgery over supplying preoperative pterosaurs with a supplemental strap-on prosthetic is another place the literature is lacking.

IV. CONCLUSION

While the pterodactyling procedure produces innumerable definite benefits in the raising of young men’s immediate and prolonged self-esteem and alleviation of dysphoria, extra steps need to be taken to ensure the sustained long term mental and physical health of those undergoing the procedure. If the surgery is successful and the implant is placed, it has a lifespan of 15 to 20 years. When it is removed, the piece is replaced with the latest appropriate prosthesis. The goal in the next 10 years is to improve the current implant offerings so as to make surgical maintenance as infrequent as possible.

BDD and self-esteem issues being targeted specifically through the BISI nodal diagnosis system, societal reintegration period for pterosaurs is astoundingly fast with positive benefits across the board, such as increased relationship longevity. A 2005 study found that roughly 35% of the 333 men who had undergone the surgery were in committed relationships, and by the end of their lives, 86% of these pairs were happily married. Speaking about the statistics, Bob Houde, president of the Pterosaur Recovery Association (PRA), said, “It is great to see that pterosaurs are a welcome member of the society. That is an accomplishment, truly. We are able to communicate with those close to us that surgery is not a wrong action, but an adaptive process, a natural, necessary, healthy process to correct those body image problems.

So often in these cases, the intention to become a more masculine, confident man goes to greater effect if the subject is proactively addressing an oft overlooked area of his body image, with regards to pterosaurs, small elbows.

The rapid medical implementation and social acceptance of the pterodactyling procedure offers a radical path forward in nodal cascation (NC) as a means of repairing self-esteem, heightening physical attributes and traits, pruning excess nodal points, and streamlining the diagnostic process, not only for young men diagnosed with a severe case of BDD, but the population at large going forward.

REFERENCES

- [1] K. A. Phillips, *The broken mirror: Understanding and treating body dysmorphic disorder*. Oxford University Press, USA, 2005.
- [2] D. J. Castle and K. A. Phillips, *Disorders of body image*. Routledge, 2002.
- [3] M. R. Munafò and J. Stevenson, “Anxiety and surgical recovery: Reinterpreting the literature,” *Journal of psychosomatic research*, vol. 51, no. 4, pp. 589–596, 2001.
- [4] Becker, Nieder, T.O, Cerwenka, I. et al., “Body Image in Young Gender Dysphoric Adults: A European Multi-Center Study,” *Arch Sex Behav*, vol. 45, pp. 559–574, 2016.
- [5] T. W. Lindgren and I. B. Pauly, “A body image scale for evaluating transsexuals,” *Archives of Sexual Behavior*, vol. 4, no. 6, pp. 639–656, 1975. [Online]. Available: 10.1007/bf01544272;https://dx.doi.org/10.1007/bf01544272
- [6] M. Mcfaddin, “Adaptive Customization: New Design Opportunities in Orthopedics, Driven by the Merging of Imaging and Surgery,” 2007.
- [7] M. B. McFarland and T. A. Petrie, “Male body satisfaction: Factorial and construct validity of the Body Parts Satisfaction Scale for men.” *Journal of counseling psychology*, vol. 59, no. 2, p. 329, 2012.

- [8] T. L. Tylka, D. Bergeron, and J. P. Schwartz, "Development and psychometric evaluation of the Male Body Attitudes Scale (MBAS)," *Body image*, vol. 2, no. 2, pp. 161–175, 2005.
- [9] J. M. Wilkinson and D. Stanley, "Posterior surgical approaches to the elbow: A comparative anatomic study," *Journal of Shoulder and Elbow Surgery*, vol. 10, no. 4, pp. 380–382, 2001. [Online]. Available: <https://doi.org/10.1067/mse.2001.116517>
- [10] W. C. Campbell, "Incision for exposure of the elbow joint," *The American Journal of Surgery*, vol. 15, no. 1, pp. 65–67, 1932. [Online]. Available: [https://doi.org/10.1016/S0002-9610\(32\)90997-0](https://doi.org/10.1016/S0002-9610(32)90997-0)
- [11] J. C. Tanner, J. Vandeput, and J. F. Olley, "The mesh skin graft," *Plast Reconstr Surg*, vol. 34, no. 3, pp. 287–292, 1964.
- [12] T. F. Cash, "Body image: past, present, and future," *Body Image*, vol. 1, no. 1, pp. 1–5, 2004. [Online]. Available: [https://doi.org/10.1016/S1740-1445\(03\)00011-1](https://doi.org/10.1016/S1740-1445(03)00011-1)